

Osteoarthritis and Cartilage



Subchondral bone changes after joint distraction treatment for end stage knee osteoarthritis

S.C. Mastbergen [†]^a, A. Ooms [†]^a, T.D. Turmezei [‡][§], J.W. MacKay [§] ^{||}, R.J. Van Heerwaarden [¶], S. Spruijt [#], F.P.J.G. Lafeber [†], M.P. Jansen [†]^{*}

[†] Department of Rheumatology & Clinical Immunology, University Medical Center Utrecht, Utrecht, the Netherlands

[‡] Department of Radiology, Norfolk & Norwich University Hospital, Norwich, United Kingdom

[§] Norwich Medical School, University of East Anglia, Norwich, United Kingdom

^{||} Department of Radiology, University of Cambridge, Cambridge, United Kingdom

[¶] Centre for Deformity Correction and Joint Preserving Surgery, Kliniek ViaSana, Mill, the Netherlands

[#] Reinier Haga Orthopaedic Centre, Zoetermeer, the Netherlands

ARTICLE INFO

Article history:

Received 17 June 2021

Accepted 22 December 2021

Keywords:

Computed tomography

Knee joint distraction

Osteoarthritis

Subchondral bone

Cortical

Trabecular

SUMMARY

Objective: Increased subchondral cortical bone plate thickness and trabecular bone density are characteristic of knee osteoarthritis (OA). Knee joint distraction (KJD) is a joint-preserving knee OA treatment where the joint is temporarily unloaded. It has previously shown clinical improvement and cartilage regeneration, indicating reversal of OA-related changes. The purpose of this research was to explore 3D subchondral bone changes after KJD treatment using CT imaging.

Design: Twenty patients were treated with KJD and included to undergo knee CT imaging before, one, and two years after treatment. Tibia and femur segmentation and registration to canonical surfaces were performed semi-automatically. Cortical bone thickness and trabecular bone density were determined using an automated algorithm. Statistical parametric mapping (SPM) with two-tailed F-tests was used to analyze whole-joint changes.

Results: Data was available of 16 patients. Subchondral cortical bone plate thickness and trabecular bone density were higher in the weight-bearing region of the most affected compartment (MAC; mostly medial). Especially the MAC showed a decrease in thickness and density in the first year after treatment, which was sustained towards the second year.

Conclusions: KJD treatment results in bone changes that include thinning of the subchondral cortical bone plate and decrease of subchondral trabecular bone density in the first two years after treatment, potentially indicating a partial normalization of subchondral bone.

© 2022 The Authors. Published by Elsevier Ltd on behalf of Osteoarthritis Research Society International.

This is an open access article under the CC BY license (<http://creativecommons.org/licenses/by/4.0/>).

Introduction

Knee osteoarthritis (OA) is characterized not only by cartilage degeneration, but by significant bone remodeling as well¹. In end-stage knee OA, bony changes include subchondral (cortical) bone

plate thickening and trabecular bone density decrease^{2,3}. The overall bone shape changes as well, most notably by widening and flattening of femoral and tibial condyles and formation of osteophytes at the edges⁴. Bone changes after (joint-preserving) knee OA treatments are not evaluated often, as these studies generally focus on improving clinical patient-reported outcomes and, to a lesser degree, increasing cartilage thickness. Knee joint distraction (KJD) is one of the joint-preserving surgical treatments for relatively young (<65 years) knee OA patients. The treatment has been evaluated in several clinical trials, where it has shown significant short- and long-term clinical improvement^{5–8}. Furthermore, KJD has demonstrated the ability to reverse OA cartilage degradation, as radiographic JSW and MRI cartilage thickness measurements showed significant short-term cartilage regeneration, which was sustained for up to ten years after treatment^{6,9–11}. Bone changes have been evaluated on plain

* Address correspondence and reprint requests to: M.P. Jansen, Department of Rheumatology & Clinical Immunology, University Medical Center Utrecht, Heidelberglaan 100, 3584CX, Utrecht, the Netherlands. Tel.: 31-88-755-1770; fax: 31-88-755-5639.

E-mail addresses: S.Mastbergen@umcutrecht.nl (S.C. Mastbergen), a.ooms@student.utwente.nl (A. Ooms), tom.turmezei@nnuh.nhs.uk (T.D. Turmezei), jw.mackay@gmail.com (J.W. MacKay), vanheerwaarden@yahoo.com (R.J. Van Heerwaarden), s.spruijt@hagaziekenhuis.nl (S. Spruijt), F.Lafeber@umcutrecht.nl (F.P.J.G. Lafeber), m.p.jansen-36@umcutrecht.nl (M.P. Jansen).

^a The first two authors contributed equally (joint first author).

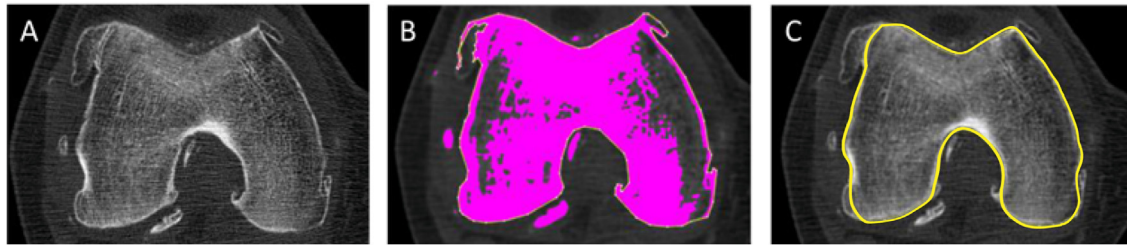

Fig. 1

Osteoarthritis and Cartilage

Example segmentation from one CT slice. (A) Axial CT slice; (B) Thresholding of bone (pink); (C) Final semi-automatic segmentation of this slice (yellow line), excluding osteophytes.

radiographs, showing a decrease in overall subchondral bone density one year after treatment with increased osteophyte formation in the first two years after treatment^{9,12}. However, bone changes after KJD have never been evaluated in three dimensions (3D), which enables measurement and visualization across the entire joint. As such, the purpose of this research was to explore subchondral cortical bone plate thickness and subchondral trabecular bone density from CT imaging before and up to two years after KJD treatment.

Materials and methods

Patients

Patients were included from two randomized controlled trials (RCTs). In one RCT, relatively young (<65 years) OA patients considered for total knee arthroplasty (TKA) were randomized to either KJD ($n = 20$) or TKA ($n = 40$) treatment. In a separate RCT, relatively young (<65 years) OA patients considered for high tibial osteotomy (HTO) were randomized to either KJD ($n = 23$) or HTO ($n = 46$). Inclusion criteria were similar between the two trials, and included Kellgren–Lawrence grade >2 (as judged by orthopedic surgeon), no history of inflammatory or rheumatoid arthritis, no primary patellofemoral OA, leg axis deviation less than 10°, and no surgical treatment of the involved knee <6 months ago^{6,13,14}. These patients were considered end-stage knee OA patients, since they exhausted conventional treatment options and required surgical intervention.

In both RCTs, after randomization to KJD treatment, patients were asked to participate in an extended imaging protocol that included CT scans. The first 20 KJD patients (irrespective of the trial from which they were included) who gave written informed consent for the extended imaging protocol were included (10 from each trial/original indication TKA or HTO, respectively).

KJD treatment was performed using an external fixation frame, fixed to the joint laterally and medially using four pairs of bone pins. During surgery the joint was distracted to a distance of 2 mm, which was gradually extended by 1 mm per day over the next three days, reaching 5 mm of total distraction. This was confirmed radiographically, after which patients were discharged. Full weight-bearing on the treated knee was allowed and encouraged, using crutches if necessary. After six weeks, patients returned to the hospital, where the frame and pins were removed, without further imposed rehabilitation protocol.

The original RCTs and the extended imaging protocol were granted ethical approval by the medical ethical review committee of the University Medical Center Utrecht (protocol numbers 10/359/E, 11/072 and 11/482/E). All patients gave written informed consent.

CT analyses

Patients underwent CT scanning with a reconstructed slice thickness of 0.45–0.5 mm, at baseline (pre-treatment) and one and two years after treatment. All CT scans were made at the UMC Utrecht using the same CT scanner and settings. All scans were performed with 120 kVp and exposure 87–232 mA. The field of view was 512x512 pixels and pixel spacing varied between 0.27 × 0.27 mm and 0.98 × 0.98 mm. The CT dose index (CTDI_{vol}) was 3.9–10 mGy and dose length product 174–495 mGy*cm.

Stradview v6.0 (University of Cambridge Department of Engineering, Cambridge, UK, in-house developed software freely available at <https://mi.eng.cam.ac.uk/Main/StradView>) was used for semi-automatic segmentation of the tibia and femur. Cortical bone mapping was used as measurement technique, as it is not limited by the CT resolution and uses an automated optimized Gaussian model fit algorithm able to measure bone thickness in the sub-millimeter range, unconstrained by the point spread function limit of the CT imaging system^{15,16}. Cortical bone thickness (mm,

Parameter	Mean ± SD or n (%)	KJD patients ($n = 16$)
Age, years		53.8 ± 6.8
BMI, kg/m ²		26.7 ± 3.4
Male sex		11 (69)
Medial MAC		14 (88)
Kellgren–Lawrence grade		
- Grade 0		0 (0)
- Grade 1		2 (13)
- Grade 2		1 (6)
- Grade 3		9 (56)
- Grade 4		4 (25)

KJD = knee joint distraction; SD = standard deviation; BMI = body mass index; MAC = most affected compartment.

Table 1

Osteoarthritis and Cartilage

Baseline parameters of included patients

referring to the subchondral bone plate as well as cortical bone in non-articular regions) was determined, and trabecular bone density (Hounsfield units, HU) was measured as part of this optimized solution from the inner cortical bone edge inwards to 12 mm beneath the mesh surface (outer bone surface). This is not the same as bone mineral density, as no dedicated phantom was scanned for calibration, but gives a reasonable approximation that enables comparisons across time points. A 3D isosurface was generated for the two bones separately through semi-automatic segmentation. This software and technique have been explained in detail previously^{17,18}. Segmentation parameters were determined scan by scan by one trained user, and osteophytes were excluded from the segmentation (see example of segmentation in Fig. 1).

Afterwards, wxRegSurf v18 (Cambridge University Engineering Department, Cambridge, UK, in-house developed software freely available at <http://mi.eng.cam.ac.uk/~ahg/wxRegSurf/>) was used for non-rigid registration of all femur and tibia surfaces to a

canonical femur and tibia respectively, using a free-form deformation model based on B-splines¹⁹. This registration was performed for the femur and tibia separately, to allow combining and comparing of surface objects from multiple scans. The canonical surfaces were created by averaging the shapes of the femurs and tibias of all patients at baseline. The vertex by vertex displacement data to the canonical surfaces of each individual scan was saved, and used to visually explore the bone shape changes between time points. Results of these shape changes can be found in the supplementary data.

Only patients for whom baseline and at least one of the two follow-up time points available were included for analysis. Since KJD has previously shown significant results mostly in the patients' most affected compartment (MAC), patients were separated into two groups based upon whether their MAC was medial or lateral. The MAC was determined at patient inclusion based on weight-bearing radiographs.

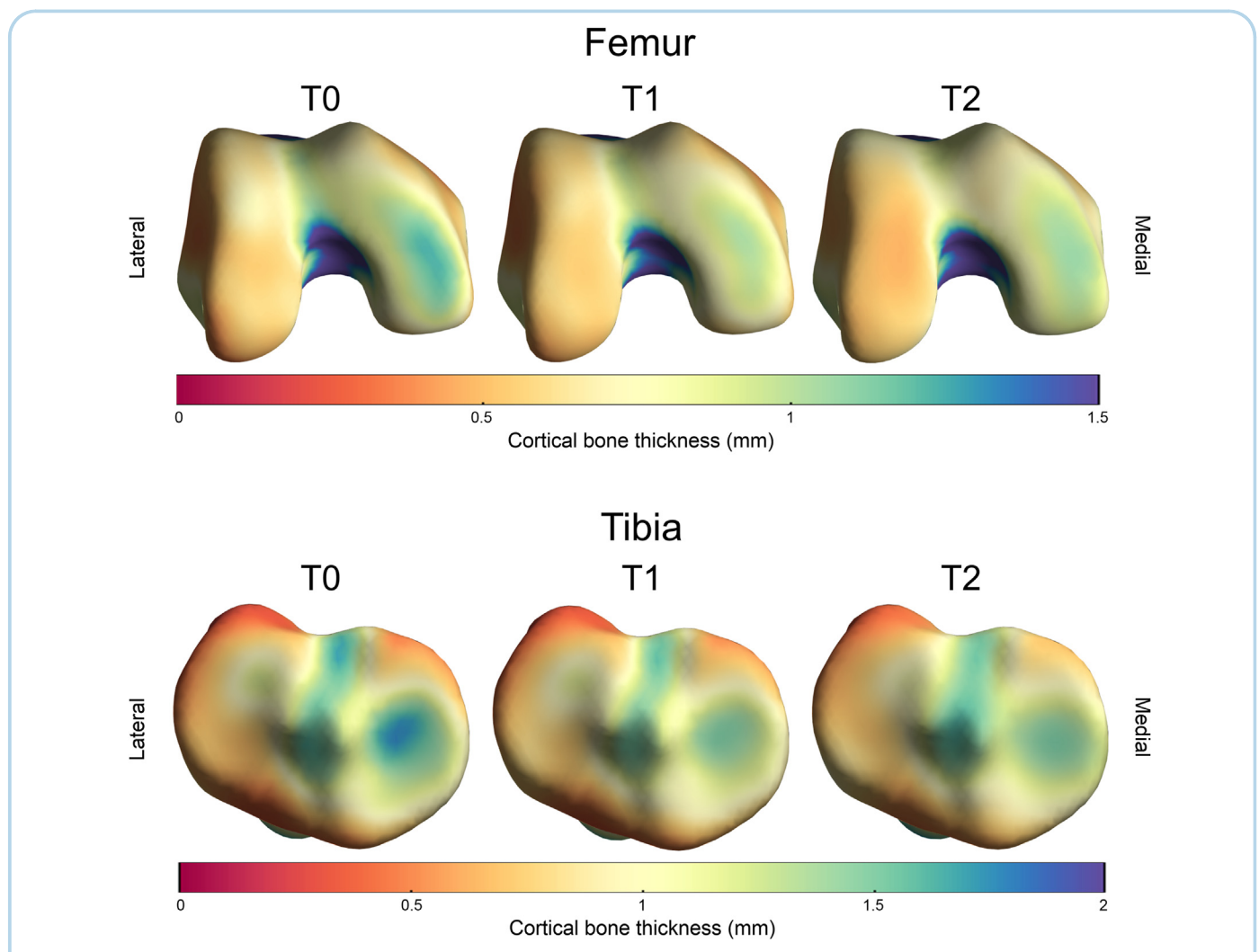


Fig. 2

Osteoarthritis and Cartilage

Average weight-bearing tibiofemoral subchondral cortical bone thickness of patients with predominantly medial compartmental osteoarthritis ($n = 14$), before (T0), one (T1) and two years (T2) after treatment with knee joint distraction, looking at the femoral articular surface from below and the tibial articular surface from above.

Statistical analyses

MATLAB R2020a and the SurfStat MATLAB package (<https://www.math.mcgill.ca/keith/surfstat/>), optimized for this specific application by Graham Treece of the University of Cambridge) were used for whole-bone, vertex-wise data analysis and visualization.

Average cortical bone thickness and trabecular density were displayed for each time point separately, by averaging data of all available patients at each time point. Statistical parametric mapping (SPM) was used for statistical analysis, which uses all subjects' values at each vertex for statistical testing and delivers vertex-wise p -value corrections for multiple comparisons at a set corrected p -value threshold using random field theory¹⁷.

SPM with two-tailed F-tests were used to calculate changes over time against a null hypothesis of no change²⁰. In all cases, a p -value < 0.05 was considered statistically significant. Although measurement and analysis of the bony parameters are performed for the

whole bone surfaces, in this study we focus attention on the subchondral cortical bone plate and trabecular density.

Results

Patients

Three patients did not have appropriate CT imaging at baseline and at least one follow-up time point, one patient could not be analyzed because of metal artefact around the joint space area at baseline, and in one patient the imaged femur shaft at baseline was too short for final analysis. This left 16 patients for tibial analyses and 15 patients for femoral analyses at baseline. These patients were all available at one-year follow-up as well, while one patient was lost to follow-up between one and two years because of additional surgery. Baseline characteristics for the 16 included patients are shown in Table 1. The MAC was predominantly the medial knee compartment (medial MAC $n = 14$; lateral MAC $n = 2$).

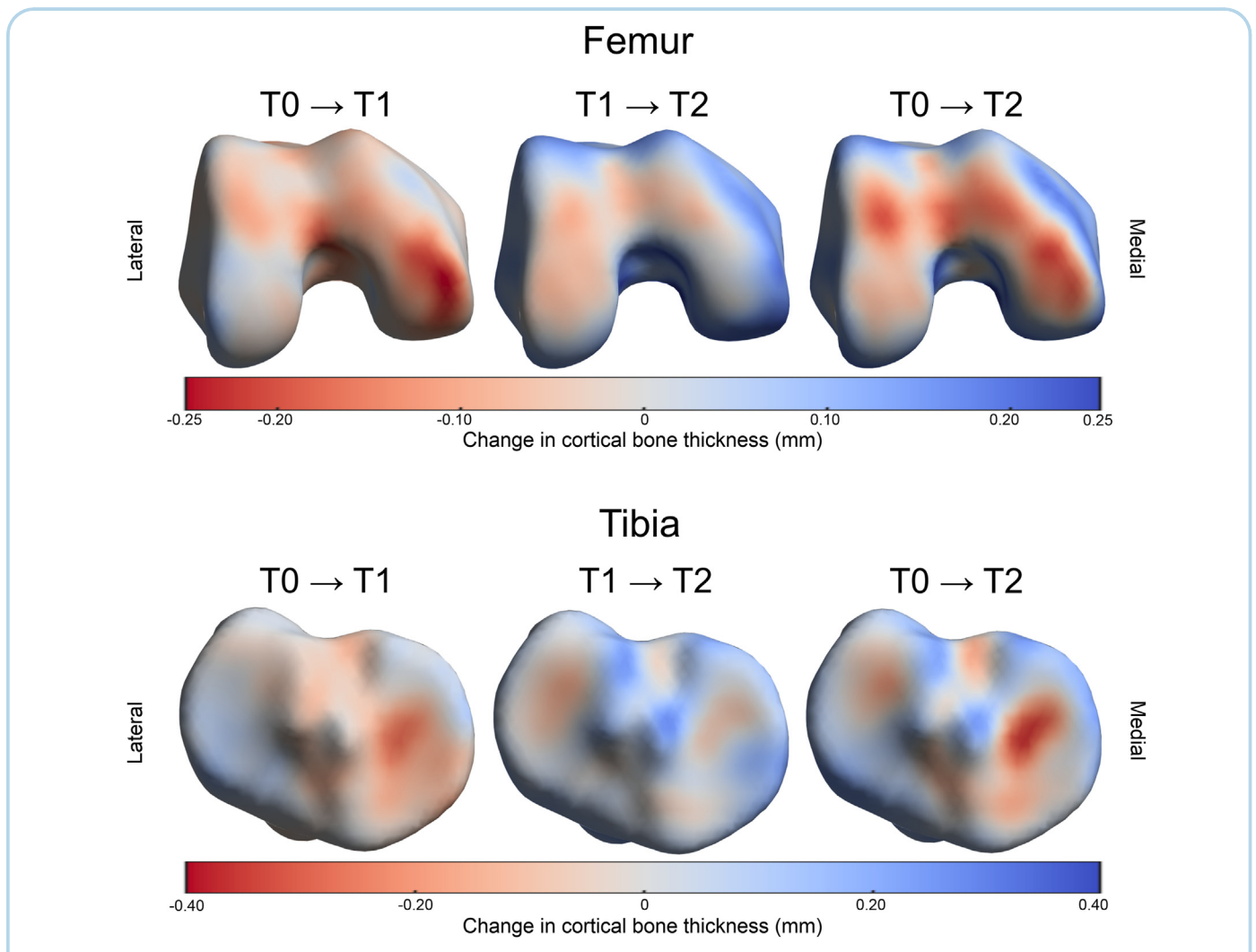


Fig. 3

Osteoarthritis and Cartilage

Cortical bone thickness changes one (left) and two (middle) years after treatment with knee joint distraction, and two years compared to one year post-treatment (right), for patients with predominantly medial compartmental osteoarthritis ($n = 14$).

Cortical bone thickness

Cortical bone thickness results for patients with a predominantly medial compartmental knee OA are shown in Fig. 2 (colorblind accessible version can be found in Supplementary Fig. S1). On average a higher thickness was seen on the medial femur and tibia compared to the lateral side for these patients, as indicated by the green-blue color on the medial side as compared to the yellow-orange elsewhere. Similarly, the average of the two patients with predominantly lateral compartmental OA showed a higher subchondral cortical bone thickness at the lateral site as compared to the medial side (Supplementary Fig. S2; colorblind accessible version Supplementary Fig. S3).

One year after treatment, the cortical subchondral bone plate thickness at the medial weight-bearing femur and tibia of the predominantly medial compartmental OA patients decreased by up to 0.25 mm, as shown in Fig. 3. Between one and two years after treatment, bone thinning was relatively small compared to the

thinning that was seen in the first year compared to baseline, showing a marginal bone thickness decrease on the lateral side as well. Cortical bone thickness around the joint margins seemed to increase between one and two years post-treatment. None of the changes between any of the time points reached statistical significance. The variance in the subchondral changes was the highest on the medial side (Supplementary Fig. S4; colorblind accessible version Supplementary Fig. S5). Patients with a predominantly lateral compartmental OA showed a similar pattern, showing a decrease in subchondral plate thickness especially on the lateral side (Supplementary Fig. S2; colorblind accessible version Supplementary Fig. S3).

Trabecular bone density

The trabecular bone density was also higher before treatment on the medial (most affected) side as compared to the lateral side, for both the tibia and femur, for patients with predominantly

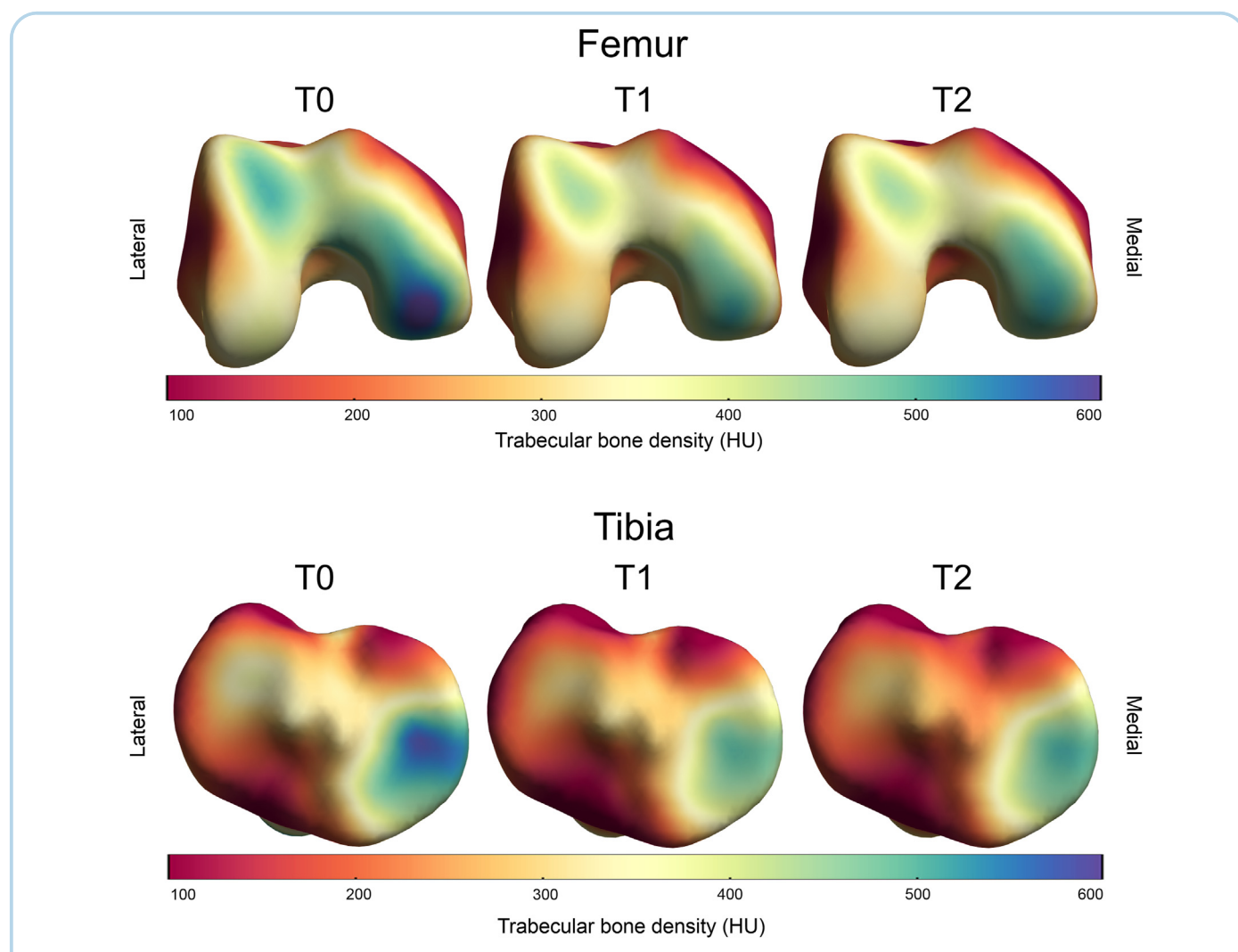


Fig. 4

Osteoarthritis and Cartilage

Trabecular bone density of patients with predominantly medial compartmental osteoarthritis ($n = 14$), before and one and two years after treatment with knee joint distraction.

medial compartmental OA as shown in Fig. 4 with green-blue colors (colorblind accessible version Supplementary Fig. S6). Similarly, the two patients with predominantly lateral compartmental OA showed a higher subchondral trabecular bone density at the lateral site as compared to the medial site (Supplementary Fig. S7; colorblind accessible version Supplementary Fig. S8).

In the first year after treatment, a decrease in trabecular density was seen throughout the entire joint, although statistically significant only for small areas on mostly the medial side where this decrease was up to approximately 80 HU over the first year (Fig. 5). Between one and two years after treatment, a (non-significant) increase throughout almost the entire joint was seen (~40 HU), except for a statistically significant decrease around the medial tibial eminence. Again, the variance in the changes was higher the

highest on the medial side (Supplementary Fig. S9; colorblind accessible version Supplementary Fig. S10).

Although differences between the medial and lateral side were less pronounced than in patients with medial compartmental OA, also patients with predominantly lateral compartmental OA showed a general decrease in trabecular bone density throughout the joint at one and two years follow-up compared to baseline (Supplementary Fig. S7; colorblind accessible version Supplementary Fig. S8).

Discussion

This exploratory study demonstrates that in end-stage OA patients, KJD treatment causes remodeling of the subchondral bone

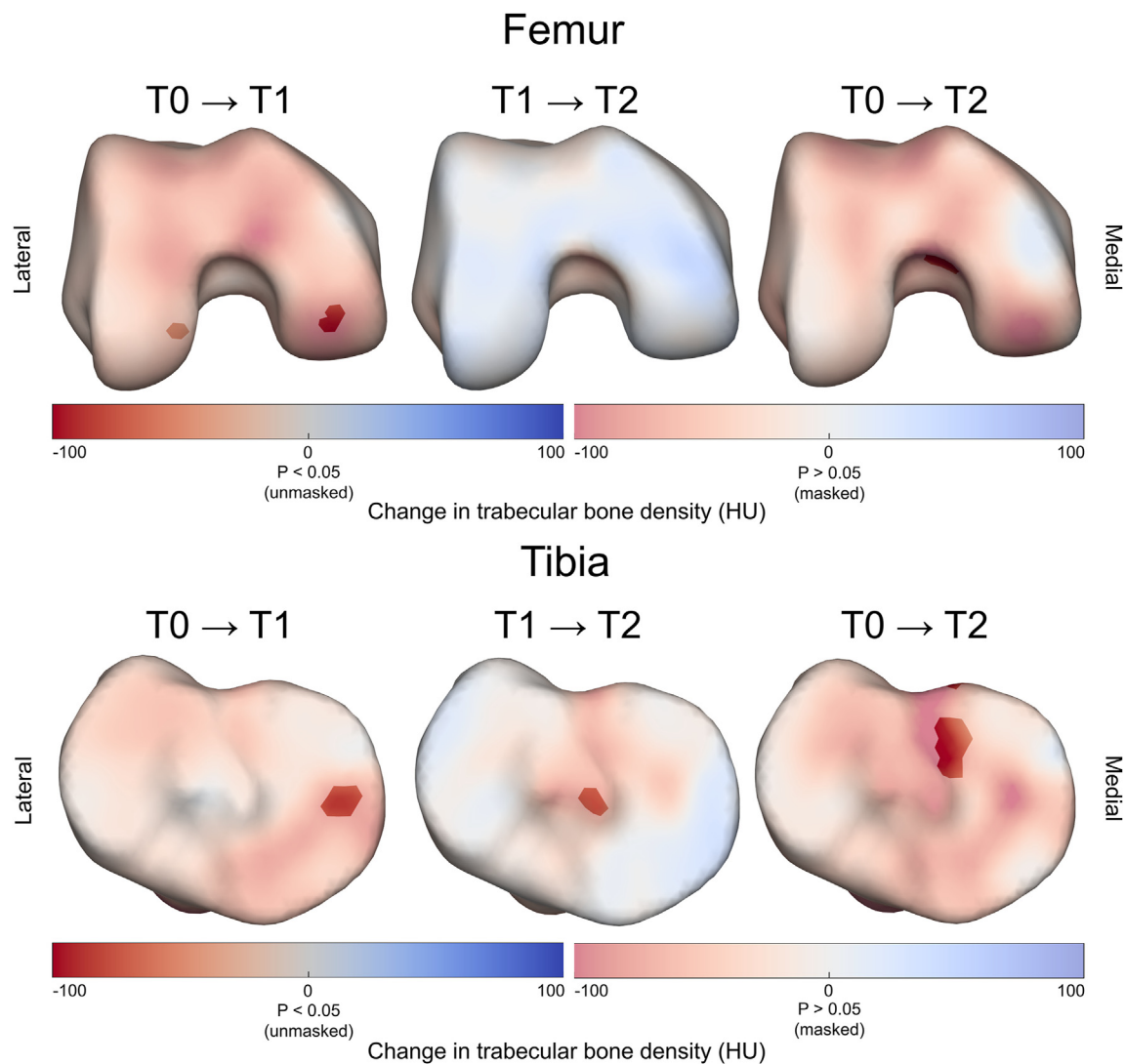


Fig. 5

Trabecular bone density changes one (left) and two (middle) years after treatment with knee joint distraction, and two years compared to one year post-treatment (right), for patients with predominantly medial compartmental osteoarthritis ($n = 14$). Statistically significant changes ($p < 0.05$) are indicated by the unmasked (brighter) regions using the left color bar, while changes that were not statistically significant ($p \geq 0.05$) are indicated by masked (duller) regions using the right color bar.

plate especially in the first year after treatment and most notably in the MAC, characterized by a decrease in subchondral cortical bone plate thickness and a decrease in subchondral trabecular thickness. These first-year changes are largely sustained throughout the second year and go paired with overall bone shape alterations (supplementary results). In the patients included in the current study, significant clinical improvement and cartilage restoration have previously been reported in the same time period^{6,10,13,14,21}. Apparently not only cartilage is repaired, but also bone shows alterations in architecture that could be considered a partial normalization. This, in combination with the fact that KJD has shown anabolic and catabolic changes in joint homeostasis as well (measured with synovial fluid biomarkers and mesenchymal stem cells), indicates KJD results in modification of the whole-joint including not only cartilage but also bone and synovial tissue activity that could, as indicated by results from other KJD studies, lead to long-term joint repair^{9,22,23}.

As the subchondral cortical bone plate is thicker in advanced OA, especially in the tibia, it was anticipated that at baseline the MAC showed a higher cortical bone thickness compared to the less affected compartment of the joint^{3,24}. Throughout the entire subchondral bone, but most evidently in the MAC, KJD appears to result in a decrease in thickness at the subchondral bone plate that is sustained at two years. Between one and two years after treatment, the cortical thickness around the joint margins seemed to increase, which might be related to formation of osteophytes in those regions, as previously shown using this same analysis technique in the hip¹⁷. This exploratory study is hampered by the absence of a matched healthy control group with CT images available. As such it is difficult to say what a normal subchondral cortical bone thickness is, particularly given the novelty of this analysis technique. However, the fact that the MAC of the OA joint seems to become more similar to the part of the joint that is less affected by OA, suggests the effects are positive and cause (at least partial) normalization of subchondral cortical bone plate thickness.

The subchondral trabecular bone density showed higher values in the MAC as well. The density decreased throughout the entire joint in the first year after treatment, likely the result of the six-week unloading, and remained decreased at two years compared to baseline despite the small increase between one and two years after treatment. This increase in the second year could be the result of natural progression, or could be somewhat increased thickening as the result of thinning in the first year after treatment. Also, values in the MAC shifted towards values observed in the least affected compartment, with the largest and most significant changes occurring in the MAC, again indicating a shift towards (partial) subchondral bone normalization.

CT analyses in patients treated with ankle distraction showed subchondral bone density normalization as well, as the overall density decreased while density in low-density (cystic) areas increased²⁵. Previous radiographic evaluations showed a significant subchondral bone density decrease one year after KJD treatment as well, and this decrease was significantly larger in patients who nine years after treatment still did not receive a TKA compared to patients who did⁹. In these studies, no differentiation between cortical plate thickness and trabecular density was made. In the present study for the first time we show that these observed density changes after joint distraction, previously seen in ankle distraction patients on ankle CTs and in KJD patients on plain knee radiographs, could be the result of a combination of both a decrease in cortical plate thickness and a decrease in trabecular density.

This study is clearly an explorative study regarding its sample size and the absence of a healthy control group as well as an

untreated matched OA group. The sample size was small, which may be why there were only small areas with statistically significant changes, although they were largely in line with the general concept. KJD is still a relatively new treatment, and CT scans are not often included in studies and especially not in regular care. The observed changes agree with those found previously on radiographs. Furthermore, the two patients with a lateral MAC could be a mirrored control group, and the fact they showed opposite results (and as such both showed the same effect for the MAC) is supportive to our conclusions. Notwithstanding, a healthy control group and a matched group of OA patients would have strengthened our conclusions significantly, although not treating patients with such severe OA for multiple years is (ethically) impossible. It also would have been worthwhile to include a calibration phantom during the CT scans, to enable measuring cortical bone mineral density, another useful parameter. Furthermore, while normal clinical quality control measures were taken with respect to the CT scans, no additional measures were taken to account for potential HU drift. Future studies should take these points into account to strengthen the concept of bone normalization upon distraction treatment as one of the underlying mechanisms of the observed clinical benefit.

In conclusion, we have shown that bone changes after KJD treatment include thinning of the subchondral cortical bone plate and decrease of subchondral trabecular bone density in the first year sustaining towards the second year.

Contributions

All authors have made substantial contributions to all three of sections (1), (2) and (3) below:

- (1) The conception and design of the study, or acquisition of data, or analysis and interpretation of data;
- (2) Drafting the article or revising it critically for important intellectual content;
- (3) Final approval of the version to be submitted.

Specifically:

Conception and design of study: SM, RH, FL, MJ.

Data acquisition: AA, RH, SS.

Data analysis and interpretation: SM, AA, TD, JM, FL, MJ.

Drafting of the article: MJ.

Critical revision of the article: SM, AA, TD, JM, RH, SS, FL.

All authors approved the manuscript for submission.

Conflict of interest

The institution of MJ, SM and FL received grants from ZonMw (Project Number 95110008) during the conduct of the study. JM reports grants and personal fees from GlaxoSmithKline, personal fees from Moximed, and grants and personal fees from GE Healthcare, outside the submitted work; RH reports consulting fees from Newclip Technics, outside the submitted work; SS reports consulting fees from Zimmer Biomet Inc, outside the submitted work; FL reports consulting fees from SynerkinePharma BV, outside the submitted work.

Role of the funding source

The sponsor was not involved in study design, collection, analysis and interpretation of data; in the writing of the manuscript; and in the decision to submit the manuscript for publication.

Acknowledgements

This project was funded by ZonMw (Project Number 95110008).

Supplementary data

Supplementary data to this article can be found online at <https://doi.org/10.1016/j.joca.2021.12.014>.

References

- Burr DB, Gallant MA. Bone remodelling in osteoarthritis. *Nat Rev Rheumatol* 2012 Nov;8(11):665–73, <https://doi.org/10.1038/nrrheum.2012.130>.
- Donell S. Subchondral bone remodelling in osteoarthritis. *EFORT Open Reviews* 2019 Jun 1;4(6):221–9, <https://doi.org/10.1302/2058-5241.4.180102>.
- Buckland-Wright C. Subchondral bone changes in hand and knee osteoarthritis detected by radiography. *Osteoarthritis Cartilage* 2004;12(Suppl 1):10–9, <https://doi.org/10.1016/j.joca.2003.09.007>.
- Neogi T. Clinical significance of bone changes in osteoarthritis. *Therapeutic Advances in Musculoskeletal Disease* 2012;4(4): 259–67, <https://doi.org/10.1177/1759720X12437354>.
- Jansen MP, Boymans TAEJ, Custers RJH, Van Geenen RCI, Van Heerwaarden RJ, Huizinga MR, et al. Knee joint distraction as treatment for osteoarthritis results in clinical and structural benefit: a systematic review and meta-analysis of the limited number of studies and patients available. *Cartilage* 2020 Jul 22, <https://doi.org/10.1177/1947603520942945>. 194760352094294.
- Jansen MP, Besselink NJ, van Heerwaarden RJ, Custers RJH, Emans PJ, Spruijt S, et al. Knee joint distraction compared with high tibial osteotomy and total knee arthroplasty: two-year clinical, radiographic, and biochemical marker outcomes of two randomized controlled trials. *Cartilage* 2019 Feb 13;12(2): 181–91, <https://doi.org/10.1177/1947603519828432>.
- Hoorntje A, Kuijter PPFM, Koenraadt KLM, Waterval-Witjes S, Kerkhoffs GMMJ, Mastbergen SC, et al. Return to sport and work after randomization for knee distraction versus high tibial osteotomy: is there a difference? *J Knee Surg* 2020 Nov 23, <https://doi.org/10.1055/s-0040-1721027>.
- Jansen MP, Mastbergen SC. Joint distraction for osteoarthritis: clinical evidence and molecular mechanisms. *Nat Rev Rheumatol* 2021 Oct 6:1–12, <https://doi.org/10.1038/s41584-021-00695-y>.
- Jansen MP, van der Weiden GS, Van Roermund PM, Custers RJH, Mastbergen SC, Lafeber FPPJG. Initial tissue repair predicts long-term clinical success of knee joint distraction as treatment for knee osteoarthritis. *Osteoarthritis Cartilage* 2018;26(12): 1604–8, <https://doi.org/10.1016/j.joca.2018.08.004>.
- Jansen MP, Maschek S, van Heerwaarden RJ, Mastbergen SC, Wirth W, Lafeber FPPJG, et al. Changes in cartilage thickness and denuded bone area after knee joint distraction and high tibial osteotomy - post-hoc analyses of two randomized controlled trials. *J Clin Med* 2021 Jan 19;10(2):368, <https://doi.org/10.3390/jcm10020368>.
- Jansen MP, Mastbergen SC, MacKay JW, Turmezei TD, Lafeber F. Knee joint distraction results in MRI cartilage thickness increase up to ten years after treatment. *Rheumatology* 2021 May 22, <https://doi.org/10.1093/rheumatology/keab456>.
- Jansen MP, Mastbergen SC, Watt FE, Willemse EJ, Vincent TL, Spruijt S, et al. Cartilage repair activity during joint-preserving treatment may be accompanied by osteophyte formation. *Appl Sci* 2021 Aug 3;11(15):7156, <https://doi.org/10.3390/app11157156>.
- van der Woude JAD, Wiegant K, van Heerwaarden RJ, Spruijt S, van Roermund PM, Custers RJH, et al. Knee joint distraction compared with high tibial osteotomy: a randomized controlled trial. *Knee Surg Sports Traumatol Arthrosc* 2017;25(3):876–86, <https://doi.org/10.1007/s00167-016-4131-0>.
- Van Der Woude JAD, Wiegant K, Van Heerwaarden RJ, Spruijt S, Emans PJ, Mastbergen SC, et al. Knee joint distraction compared with total knee arthroplasty a randomised controlled trial. *Bone and Joint Journal* 2017;99-B(1):51–8, <https://doi.org/10.1302/0301-620X.99B1.BJJ-2016-0099.R3>.
- Treece GM, Gee AH, Mayhew PM, Poole KES. High resolution cortical bone thickness measurement from clinical CT data. *Med Image Anal* 2010 Jun 1;14(3):276–90, <https://doi.org/10.1016/j.media.2010.01.003>.
- Treece G, Gee A. Cortical bone mapping: measurement and statistical analysis of localised skeletal changes. *Curr Osteoporos Rep* 2018 Oct 1;16(5):617, <https://doi.org/10.1007/S11914-018-0475-3>.
- Turmezei TD, Treece GM, Gee AH, Fotiadou AF, Poole KES. Quantitative 3D analysis of bone in hip osteoarthritis using clinical computed tomography. *Eur Radiol* 2016 Jul 1;26(7): 2047–54, <https://doi.org/10.1007/s00330-015-4048-x>.
- MacKay JW, Kaggie JD, Treece GM, McDonnell SM, Khan W, Roberts AR, et al. Three-dimensional surface-based analysis of cartilage MRI data in knee osteoarthritis: validation and initial clinical application. *J Magn Reson Imag* 2020 Oct 24;52(4): 1139–51, <https://doi.org/10.1002/jmri.27193>.
- Rueckert D, Frangi AF, Schnabel JA. Automatic construction of 3-D statistical deformation models of the brain using nonrigid registration. *IEEE Trans Med Imag* 2003 Aug;22(8):1014–25, <https://doi.org/10.1109/TMI.2003.815865>.
- Turmezei TD, Treece GM, Gee AH, Sigurdsson S, Jonsson H, Aspelund T, et al. Quantitative 3D imaging parameters improve prediction of hip osteoarthritis outcome. *Sci Rep* 2020 Dec 1;10(1):1–11, <https://doi.org/10.1038/s41598-020-59977-2>.
- Jansen MP, Maschek S, Van Heerwaarden RJ, Mastbergen SC, Wirth W, Lafeber FP, et al. Knee joint distraction is more efficient in rebuilding cartilage thickness in the more affected compartment than high tibial osteotomy in patients with knee osteoarthritis. *Osteoarthritis Cartilage* 2019 Apr;27(1):S330–1, <https://doi.org/10.1016/j.joca.2019.02.736>.
- Watt FE, Hamid B, Garriga C, Judge A, Hrusecka R, Custers RJH, et al. The molecular profile of synovial fluid changes upon joint distraction and is associated with clinical response in knee osteoarthritis. *Osteoarthritis Cartilage* 2020 Jan;28(3):324–33, <https://doi.org/10.1016/j.joca.2019.12.005>.
- Sanjurjo-Rodriguez C, Altaie A, Mastbergen S, Baboolal T, Welting T, Lafeber F, et al. Gene expression signatures of synovial fluid multipotent stromal cells in advanced knee osteoarthritis and following knee joint distraction. *Front Bioeng Biotechnol* 2020 Oct 14;8:1178, <https://doi.org/10.3389/fbioe.2020.579751>.
- Tomiyama Y, Koga H, Mochizuki T, Omori G, Koga Y, Tanifuji O, et al. The relationship between knee osteoarthritis and femoral distal cortical bone thickness. case control study from the matsudai knee osteoarthritis survey. *Osteoarthritis Cartilage* 2020 Apr 1;28:S208–9, <https://doi.org/10.1016/j.joca.2020.02.340>.
- Intema F, Thomas TP, Anderson DD, Elkins JM, Brown TD, Amendola A, et al. Subchondral bone remodeling is related to clinical improvement after joint distraction in the treatment of ankle osteoarthritis. *Osteoarthritis Cartilage* 2011 Jun 1;19(6): 668–75, <https://doi.org/10.1016/j.joca.2011.02.005>.